

# Platelet-rich Plasma in Orthopaedic Applications: Evidence-based Recommendations for Treatment

Wellington K. Hsu, MD  
Allan Mishra, MD  
Scott R. Rodeo, MD  
Freddie Fu, MD  
Michael A. Terry, MD  
Pietro Randelli, MD  
S. Terry Canale, MD  
Frank B. Kelly, MD

## JAAOS Plus Webinar

Join Dr. Hsu, Dr. Rodeo, and Dr. Fu for the JAAOS interactive webinar discussing "Platelet-rich Plasma in Orthopaedic Applications: Evidence-based Recommendations for Treatment," on Tuesday, December 10, at 9 PM Eastern. The moderator will be William N. Levine, MD, the *Journal's* Deputy Editor for Upper Extremity topics.

To join and to submit questions in advance, please visit the OrthoPortal website: <http://orthoport.aaos.org/jaaos/>

*J Am Acad Orthop Surg* 2013;21:739-748

<http://dx.doi.org/10.5435/JAAOS-21-12-739>

Copyright 2013 by the American Academy of Orthopaedic Surgeons.

## Abstract

Autologous platelet-rich plasma (PRP) therapies have seen a dramatic increase in breadth and frequency of use for orthopaedic conditions in the past 5 years. Rich in many growth factors that have important implications in healing, PRP can potentially regenerate tissue via multiple mechanisms. Proposed clinical and surgical applications include spinal fusion, chondropathy, knee osteoarthritis, tendinopathy, acute and chronic soft-tissue injuries, enhancement of healing after ligament reconstruction, and muscle strains. However, for many conditions, there is limited reliable clinical evidence to guide the use of PRP. Furthermore, classification systems and identification of differences among products are needed to understand the implications of variability.

The healthcare environment is changing rapidly, and recently there has been increased use of platelet-rich plasma (PRP) in orthopaedic applications. However, surgeons often have little guidance with regard to its indications and cost-effectiveness. The continuous call for data in the orthopaedic community has led to a higher quantity and quality of studies reporting the use of PRP. In February 2011, the American Academy of Orthopaedic Surgeons hosted a forum involving expert clinicians and scientists in the field of PRP therapy who presented the best available level I through III clinical studies reporting on the use of PRP in the treatment of orthopaedic conditions.<sup>1</sup> In this article, we examine several level I studies,<sup>2-16</sup> level II studies,<sup>17-24</sup> and level III studies<sup>25-30</sup> on the use of PRP in the treatment of orthopaedic conditions.

## Pathophysiology

Since 1950, PRP has been used to manage dermatologic and oromaxillofacial conditions.<sup>31,32</sup> More recently, interest has grown exponentially in the potential use of PRP in orthopaedic applications such as bone formation and soft-tissue injury, and as an adjunct in surgical reconstruction procedures.

PRP is defined as "a sample of autologous blood with concentrations of platelets above baseline values."<sup>33</sup> It is created through a two-phase centrifugation process called plasma-pheresis, in which liquid and solid components of anticoagulated blood are separated. The first phase consists of an initial soft spin (1,200 to 1,500 RPM) with a relatively low gravitational force in which plasma and platelets are separated from red blood cells and white blood cells

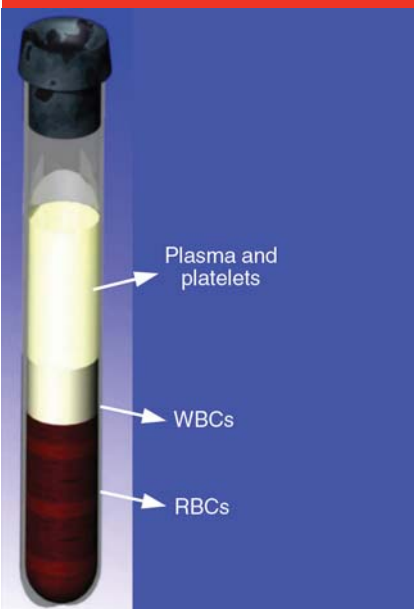
**Figure 1**

Illustration demonstrating separation of the red blood cells (RBCs) and white blood cells (WBCs) from the platelet-rich plasma (plasma and platelets) following the two-step centrifugation process.

(WBCs). The second phase, or hard spin (4,000 to 7,000 RPM), is performed to further concentrate the

platelet-rich and platelet-poor plasma components (Figure 1). The necessity of this phase is controversial, as some commercial formulations do not implement this process. Furthermore, it is unclear what potential benefits platelet-poor plasma may have on tissue healing.<sup>34</sup>

In addition to platelets, PRP contains other cell types with potentially beneficial effects in tissue healing. WBCs such as monocytes and polymorphonuclear neutrophils may trigger a localized inflammatory effect. Although some investigators believe that this inflammatory effect is critical to the tissue repair process, neutrophils have been hypothesized to impede healing.<sup>35</sup> The inclusion of WBCs in the PRP preparation varies depending on the particular indication.

Proteins such as platelet-derived growth factor (PDGF), vascular endothelial growth factor, endothelial cell growth factor, and basic fibroblast growth factor can be detected at high concentrations in PRP; consequently, many investigators have postulated that PRP may be benefi-

cial in conditions that require tissue healing.<sup>33,36</sup> In fact, Wasterlain et al<sup>36</sup> recently demonstrated that local intratendinous injection of PRP can lead to a systemic ergogenic effect, temporarily increasing serum levels of insulin-like growth factor-1, vascular endothelial growth factor, and basic fibroblast growth factor. Conversely, other proteins present in PRP have demonstrated inhibitory effects, such as transforming growth factor (TGF)- $\beta$ 1, which may lead to variable clinical results in certain applications.<sup>37</sup>

The exact role of thrombin in PRP has been debated. Thrombin and/or calcium chloride is necessary to catalyze the conversion of fibrinogen to fibrin, but it also induces platelets to secrete growth factors. Some data, however, suggest that exogenous thrombin activation of PRP may actually diminish its ability to induce bone formation compared with non-thrombin-activated PRP.<sup>38</sup>

More than 40 commercial systems exist that claim to concentrate whole blood into a platelet-rich substance. However, many factors contribute to

From the Department of Orthopaedic Surgery, Northwestern University Feinberg School of Medicine, Chicago, IL (Dr. Hsu and Dr. Terry), the Department of Orthopaedic Surgery, Stanford University Medical Center, Stanford, CA (Dr. Mishra), the Department of Orthopaedic Surgery and the Research Department, Hospital for Special Surgery, New York, NY (Dr. Rodeo), the Department of Orthopaedic Surgery, University of Pittsburgh, Pittsburgh, PA (Dr. Fu), the Department of Orthopaedic Surgery, University of Milan, Milan, Italy (Dr. Randelli), the Department of Orthopaedic Surgery, University of Tennessee—Campbell Clinic, Memphis, TN (Dr. Canale), and Forsyth Street Orthopaedics, Macon, GA (Dr. Kelly).

Dr. Hsu or an immediate family member is a member of a speakers' bureau or has made paid presentations on behalf of Graftys, Medtronic Sofamor Danek, Pioneer Surgical, Stryker, Terumo Medical, and Zimmer; has received research or institutional support from Baxter, Medtronic Sofamor Danek, and Pioneer Surgical; and serves as a board member, owner, officer, or committee member of the American Academy of Orthopaedic Surgeons (AAOS), the Lumbar Spine Research Society, and the North American Spine Society. Dr. Mishra or an immediate family member has received royalties from Biomet and ThermoGenesis, is an employee of BioParadox, and has stock or stock options held in BioParadox and ThermoGenesis. Dr. Rodeo or an immediate family member serves as a paid consultant to Smith & Nephew and has stock or stock options held in Cayenne Medical. Dr. Fu or an immediate family member has received royalties from ArthroCare; is an employee of and has stock or stock options held in Stryker; and serves as a board member, owner, officer, or committee member of the AAOS, the American Orthopaedic Society for Sports Medicine, the Orthopaedic Research and Education Foundation (OREF), and the International Society of Arthroscopy, Knee Surgery, and Orthopaedic Sports Medicine. Dr. Terry or an immediate family member has received royalties from, serves as a paid consultant to, has received research or institutional support from, and has received nonincome support (such as equipment or services), commercially derived honoraria, or other non-research-related funding (such as paid travel) from Smith & Nephew. Dr. Randelli or an immediate family member is a member of a speakers' bureau or has made paid presentations on behalf of and has received research or institutional support from Biomet; serves as a paid consultant to DePuy; and serves as a board member, owner, officer, or committee member of the European Society of Sports Traumatology, Knee Surgery & Arthroscopy. Dr. Canale or an immediate family member serves as a board member, owner, officer, or committee member of the AAOS, Bioworks, the Campbell Foundation, and OREF. Dr. Kelly or an immediate family member serves as a board member, owner, officer, or committee member of OREF and the Twentieth Century Orthopaedic Association.

**Table 1**

<b>Common Platelet-rich Plasma Formulations</b>			
<b>System</b>	<b>Type</b>	<b>Whole Blood Volume (mL)</b>	<b>Centrifuge Time (min)</b>
Cascade (Musculoskeletal Transplant Foundation) <sup>39</sup>	P-PRF	18	6
GPS III (Biomet) <sup>39</sup>	P-LRP	55	15
Magellan (Arteriocyte Medical Systems) <sup>39</sup>	P-LRP	26	17
ACP (Arthrex) <sup>40,41</sup>	P-PRP	10	5
SmartPReP (Harvest Technologies) <sup>42</sup>	P-LRP	60	16
Symphony II (DePuy) <sup>43</sup>	P-LRP	54	5

P-LRP = platelet-leukocyte-rich plasma, P-PRF = pure platelet-rich fibrin, P-PRP = pure platelet-rich plasma

the variable content and, subsequently, to the performance of PRP from different preparation methods (Table 1). First, the final platelet concentration varies not only between techniques but also within a given technique.<sup>39,44-46</sup> The final platelet concentration of any PRP product depends on the initial volume of whole blood, the platelet recovery efficiency of the chosen technique, the final volume of plasma used to suspend concentrated platelets, the relative concentration of WBCs and/or red blood cells, and the concomitant use of thrombin. Furthermore, individual patient factors such as comorbidities, age, and circulation lead to differences in growth factor and cell content.<sup>45</sup>

A higher concentration or absolute number of platelets within PRP does not necessarily lead to an enhanced tissue healing effect. In fact, Giusti et al<sup>47</sup> proposed that the most efficacious platelet concentration for tissue healing is  $1.5 \times 10^6$  platelets per microliter. In addition, the dose-response curve is not linear, and a saturation effect has been described in which an inhibitory cascade ensues once a sufficiently high concentration of platelets is reached. Because platelets can exert the greatest influence on healing during or immediately after the inflammatory phase

**Table 2**

<b>Sports Medicine Platelet-rich Plasma Classification System</b>		
<b>PRP Type<sup>a</sup></b>	<b>White Blood Cells (WBCs)</b>	<b>Activated?</b>
1	Increased over baseline	No
2	Increased over baseline	Yes
3	Minimal or no WBC	No
4	Minimal or no WBC	Yes

PRP = platelet-rich plasma  
<sup>a</sup> Any PRP type can have an associated subtype A or subtype B. Subtype A has  $\geq 5$  times the concentration of platelets in the final preparation compared to baseline. Subtype B has  $< 5$  times the concentration of platelets in the final preparation compared to baseline. Adapted with permission from Mishra A, Harmon K, Woodall J, Vieira A: Sports medicine applications of platelet rich plasma. *Curr Pharm Biotechnol* 2012;13(7):1185-1195.

of injury, some authors have postulated that the timing of the administration of PRP has a greater impact on healing than does the number of platelets.<sup>22</sup>

The absence of a validated classification system that identifies crucial differences between PRP formulations makes it difficult to compare studies. In an attempt to standardize different PRP systems, both DeLong et al<sup>35</sup> and Mishra et al<sup>48</sup> have proposed systems that classify PRP systems by activation mechanism, platelet number, and/or cell content. Although the systems have yet to be validated in the literature, they represent an important step in furthering this area of research (Table 2).

## Bone Healing

PRP has demonstrated osteogenic properties in several in vitro and pre-clinical studies;<sup>49,50</sup> however, clinical reports have not been as promising. In a prospective observational study involving 123 foot and ankle fusions in 62 patients with risk factors for nonunion, autologous platelet concentrate (APC) was used in 67 procedures, and APC and bone graft were used in 56 procedures.<sup>17</sup> Because the 6% nonunion rate for all patients was below historical outcomes, the authors concluded that APC might be beneficial in this patient population. However, these patients under-

went a variety of procedures (ankle, hindfoot, midfoot, and forefoot surgery), and the type of bone graft used (ie, allograft, autograft) varied based on surgeon choice.

In a level III prospective study, Tsai et al<sup>25</sup> reported lumbar posterolateral spine fusion rates with local bone graft in 67 consecutive patients, 34 of whom were treated with additional platelet glue. At 2-year follow-up, there was no difference in nonunion rate (15%, platelet glue; 10%, control group) as determined on flexion-extension radiographs and fine-cut CT scans. Similarly, in a retrospective cohort study of 76 consecutive patients who underwent posterolateral lumbar fusion, the nonunion rates at clinical follow-up of  $\geq 24$  months did not differ significantly between iliac crest bone graft plus platelet-gel preparation compared with autologous bone graft alone (25% and 17%, respectively;  $P = 0.18$ ).<sup>26</sup> Weiner and Walker<sup>27</sup> demonstrated a significantly lower fusion rate with the use of autologous growth factors from PRP and autograft in single-level posterolateral lumbar fusion compared with iliac crest bone graft alone (62% and 91%, respectively;  $P < 0.05$ ). The addition of PRP to autograft for posterolateral and interbody spine fusion does not appear to confer any benefit in fusion rates and, in fact, it may be detrimental.

Currently, limited clinical evidence exists demonstrating any beneficial effects from the use of PRP in bone healing applications. The available evidence indicates that PRP is not efficacious either alone or as an adjunct to local bone graft in these applications.

### Cartilage Healing

PRP contains factors that have been shown to be critical in joint repair,

such as TGF- $\beta$ 1, thrombospondin-1, and insulin-like growth factor.<sup>51</sup> Consequently, its use has been proposed in patients with symptomatic cartilage defects or osteochondral lesions.

In a level I study in which 78 patients with bilateral knee osteoarthritis were randomized to receive a single WBC-filtered PRP injection, two PRP injections 3 weeks apart, or a single saline injection, both PRP groups were found to have significantly better outcomes than the control group 6 months after treatment.<sup>2</sup> In a separate level I randomized controlled trial (RCT) in 120 patients, Cerza et al<sup>3</sup> reported significantly better clinical outcomes up to 24 weeks after a local injection of PRP compared with injection of hyaluronic acid ( $P < 0.001$ ). Conversely, in an RCT of 109 patients, Filardo et al<sup>4</sup> demonstrated that although intra-articular PRP injections can offer significant clinical improvement up to 1 year after treatment, these results were not better compared with hyaluronic acid injections. Furthermore, the authors of a Clinical Practice Guideline sponsored by the American Academy of Orthopaedic Surgeons were “unable to recommend for or against growth factor injections and/or platelet rich plasma for patients with symptomatic OA of the knee.”<sup>52</sup>

One case-control clinical study has been published to date on the management of cartilage defects with PRP.<sup>18</sup> In this level II study, 32 patients with symptomatic osteochondral lesions of the talus classified on CT scan using the Ferkel system were randomized to receive intra-articular injections of either hyaluronic acid or PRP. At 28-week follow-up, patients who received PRP demonstrated significantly greater improvements in pain, stiffness, and function scores compared with those treated with hyaluronic

acid ( $P < 0.0001$ ). Eighty-seven percent of patients enrolled in the PRP group obtained good results, which led these authors to conclude that PRP should be considered as a first-line treatment of symptomatic osteochondral lesions of the talus. Although preliminary evidence exists, further study is required before conclusions can be made regarding the efficacy of PRP in the management of osteochondral lesions and knee osteoarthritis.

### Chronic Tendinopathy

Elbow epicondylitis, which is characterized by failure of the normal tendon repair mechanism, is a common malady that leads to chronic pain and decreased function in activities of daily living. Although treatment recommendations range from bracing, physiotherapy, and steroid injections to arthroscopic or open débridement, some investigators have indicated that the local delivery of humoral mediators may enhance tendon healing and lead to improved clinical outcomes.

In a controlled trial comparing local injection of either PRP formulation containing WBCs or bupivacaine in 20 patients with chronic elbow epicondylar tendinosis, Mishra and Pavelko<sup>19</sup> demonstrated significant improvement in clinical outcomes in visual analog scale (VAS) and Mayo elbow scores at 8 weeks after treatment with PRP ( $P = 0.001$  and  $P = 0.008$ , respectively). Patients treated with PRP had a 93% reduction in pain compared with baseline at an average follow-up of 25.6 months ( $P < 0.0001$ ). Thanasis et al<sup>5</sup> compared clinical outcomes in 28 patients with the same condition who were randomized to local injection of either autologous whole blood or PRP in a level I study. Although VAS score improvements

were reported at every follow-up interval up to 6 months in the PRP group, the only statistically significant difference was seen at the 6-week time point.

Using the same methodology as did Mishra and Pavelko,<sup>19</sup> a different group of researchers compared local injection of PRP with corticosteroid for lateral epicondylitis in a level I study of 100 patients; they published one article reporting on the 1-year follow-up results<sup>7</sup> and a second article on the 2-year follow-up results.<sup>6</sup> Significantly greater reduction in VAS scores was achieved with PRP measured at each time point up to 24 months after injection ( $P < 0.0001$ ). Comparison of outcomes at 1- and 2-year follow-up demonstrated that clinical scores in the corticosteroid group steadily declined, whereas those of the PRP group were maintained.<sup>6</sup> These studies suggest that PRP formulations containing WBCs improve patient outcomes compared with local injection of anesthetic, whole blood, or corticosteroid.

The results have not been as promising for other tendinopathies. In a level I RCT comparing local injection of PRP to saline for Achilles tendinopathy in conjunction with eccentric exercises, de Vos et al<sup>8</sup> reported no difference in the improvement of clinical outcome up to a 24-week follow-up. In a follow-up study, members of the same research group randomized 54 patients diagnosed with chronic Achilles tendinopathy to blinded injections containing either PRP or saline in addition to a training program.<sup>9</sup> Although patients in both groups had improved clinical outcomes 1 year after injection, there was no significant difference in benefit. In a prospective level III study, Fildardo et al<sup>28</sup> studied the utility of PRP injection for refractory jumper's knee in 31 patients who were treated with either local injection of PRP or exercise. At 6-month follow-up, pa-

tients who received PRP demonstrated a greater activity level; however, all other outcome measures, including VAS and pain level evaluation, did not differ significantly from the control group. Gosens et al<sup>10</sup> demonstrated that, for patients previously treated with cortisone, ethoxysclerol, and/or surgery for patellar tendinopathy, PRP did not confer as much improvement in VAS scores as it did in patients who had had no prior intervention.

Although the cost-effectiveness of treatment is unclear, the clinical evidence suggests that local injection of PRP containing WBCs may be beneficial to patients with chronic elbow epicondylitis refractory to standard nonsurgical treatment. However, the results of PRP treatment of other chronic tendinopathies are not as clear.

### Surgical Repair of Acute Soft-tissue Injuries

Because of the rich source of growth factors in PRP, it has been suggested that administering PRP in the setting of acute soft-tissue injuries could provide enhanced healing, thus facilitating an early return to sports.<sup>20,29</sup> Tendon healing is typically characterized by an initial inflammatory response that is associated with the influx of factors such as PDGF and TGF- $\beta$  (within 2 days), resulting in angiogenesis (2 to 3 days), and collagen synthesis (3 to 5 days).<sup>53</sup> Because PRP contains these critical growth factors that can aid in the inflammatory response, its utility may be greatest when administered early in the healing period.<sup>54</sup>

### Anterior Cruciate Ligament Reconstruction

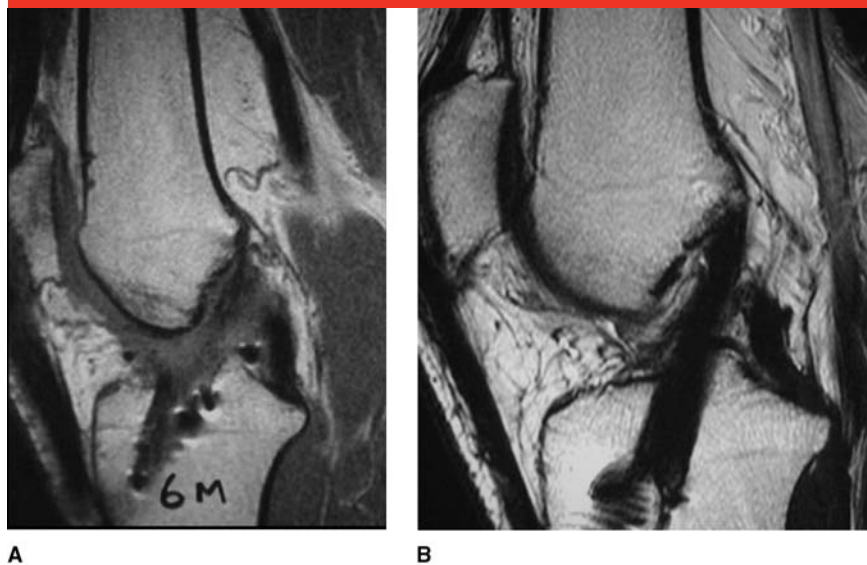
Anterior cruciate ligament (ACL) reconstruction has traditionally been considered a successful procedure

with excellent long-term results and patient satisfaction. Maturation of the tendon graft is necessary for optimal biomechanical strength and return to activity. Graft remodeling may be accelerated by the actions of PDGF, TGF- $\beta$ 1, and insulin-like growth factor-1.<sup>29</sup> The intra-articular biologic environment presents challenges to tissue healing that may lead to suboptimal results. For example, this anatomic area is not only poorly vascularized but also produces synovial fluid containing proteases that prevent fibrin clot formation, which is normally required for initial wound healing.<sup>55</sup> Furthermore, this contained milieu may not deliver important growth factors for healing.

In vitro studies have demonstrated the ability of PRP to improve ACL cell viability and function.<sup>43</sup> Thus, treatments have been proposed to increase both histologic metrics in repair and remodeling at the midsubstance of the reconstructed ACL as well as within the patellar tendon harvest site in patients treated with bone-patellar tendon-bone autografts.<sup>56</sup> Early administration of PRP during the inflammatory process may lead to an accelerated healing cascade that is shorter than the typical 1-year period expected for full graft maturation.<sup>56</sup>

Radice et al<sup>29</sup> conducted a prospective single-blind study of 50 patients who were treated with either ACL autograft alone or ACL autograft with application of PRP gel at the time of surgery. At 1-year follow-up, it was found that application of PRP gel resulted in significantly faster biologic maturation than did autograft alone as measured on MRI (177 and 369 days, respectively;  $P < 0.001$ ) (Figure 2). Similarly, in an RCT with 108 patients, Orrego et al<sup>21</sup> demonstrated that the addition of platelet concentrate to a semitendinosus-gracilis graft and to the femoral tun-

Figure 2



Sagittal T2-weighted magnetic resonance images of the knee obtained 6 months after anterior cruciate ligament reconstruction with bone–patellar tendon–bone graft without platelet-rich plasma (PRP) (A) and 5 months after reconstruction with PRP (B). A more homogeneous signal was demonstrated in grafts with PRP, which suggests a quicker maturation rate. (Reproduced with permission from Radice F, Yáñez R, Gutiérrez V, Rosales J, Pinedo M, Coda S: Comparison of magnetic resonance imaging findings in anterior cruciate ligament grafts with and without autologous platelet-derived growth factors. *Arthroscopy* 2010;26[1]:50-57.)

nel led to a significantly higher rate of graft maturation 6 months after reconstruction, signified by low-intensity signal on MRI ( $P = 0.036$ ). In contrast, Silva and Sampaio<sup>20</sup> applied PRP in the femoral tunnels in 30 patients and found no difference in MRI findings of the signal intensity of fibrous interzone in the tunnels 3 months after surgery. The differences in this study<sup>20</sup> may be partially explained by the shorter time point of radiographic imaging and smaller number of patients than in either of the other two studies.<sup>21,29</sup> A systematic review of eight controlled clinical trials concluded that the addition of platelet concentrates to ACL reconstruction may have a 20% to 30% beneficial effect on graft maturation.<sup>57</sup>

Histologic analysis of ACL grafts following PRP application also suggests enhanced maturation. Sánchez

et al<sup>56</sup> reported results in 37 patients who had second-look arthroscopies after ACL reconstruction with autogenous hamstring grafts with and without injection of a PRP preparation rich in growth factors. Both gross morphology and histologic evaluation of graft biopsies demonstrated improvements in graft remodeling and the amount of new connective tissue enveloping the graft, as well as a higher graft thickness and synovial coverage rating for patients treated with PRP. Although the period of time from index ACL surgery to second-look arthroscopy varied widely, the authors concluded that use of PRP in vivo may enhance the ligamentization process in tendon grafts.

In a level I study, Nin et al<sup>11</sup> randomized 100 patients with ACL reconstruction with patellar tendon allograft to receive or not receive

platelet-enriched gel. In the investigational group, gel was sutured into the allograft and applied in the tibial tunnel. At a mean follow-up of 2 years and based on clinical and radiographic outcomes according to the International Knee Documentation Committee score, KT-1000 arthrometer (MEDmetric), plain radiography, and MRI, the authors concluded that there were no significant differences in any parameter. The variability in clinical outcomes could be attributed to several factors, including PRP preparation/centrifugation, graft choice, rehabilitation protocols, and application technique. These findings were supported by Magnussen et al,<sup>58</sup> who demonstrated that the use of PRP in allograft ACL reconstructions did not lead to differences in patient-reported outcomes at 2-year follow-up.

More than 40% of patients who undergo ACL reconstruction with a single-bundle patellar tendon autograft report residual symptoms (eg, pain, sensory problems) at the donor site.<sup>59</sup> In an RCT involving 40 patients, Cervellin et al<sup>12</sup> studied the effect of the addition of autologous PRP gel sutured into the patellar and tibial bone plug harvest site. Although VAS scores were not significantly different at 12-month follow-up, Victorian Institute of Sport Assessment questionnaire scores, which have been validated to quantify knee function in subjects with patellar tendinopathy,<sup>60</sup> were significantly higher in patients treated with PRP ( $P = 0.041$ ), suggesting greater satisfaction with knee function. In a separate level I randomized study, 12 patients who received 20 to 40 mL of PRP gel at the patellar tendon defect were compared with 15 patients who did not receive PRP.<sup>13</sup> At 6-month follow-up MRI examination, the patellar tendon gap area was found to be significantly smaller

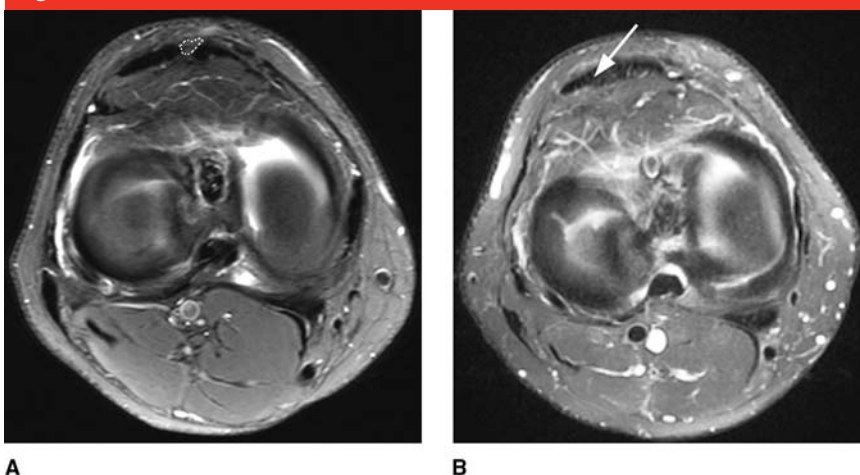
in the PRP group ( $P = 0.046$ ) (Figure 3). Furthermore, immediate postoperative VAS scores were lower in the investigational group than in the control group ( $P = 0.02$ ). Based on these findings, the authors concluded that PRP can both enhance tendon healing within the patellar tendon defect and contribute anti-inflammatory effects that may modulate pain after surgery.

### Rotator Cuff Repair

Five level I and II controlled studies have compared results after surgical repair of rotator cuff injuries with and without the adjunctive use of PRP. Castricini et al<sup>14</sup> reported no significant difference in Constant scores and tendon scores graded on MRI up to 16 months after primary arthroscopic rotator cuff repair with or without the use of autologous platelet-rich fibrin matrix (PRFM). These authors concluded that PRP had no demonstrable benefit for small to medium-size rotator cuff tears.

Similarly, in a level II study involving 79 patients in whom reattachment of the rotator cuff was performed with suture anchors, the clinical scores in the group with PRFM sutured in the tendon-bone interface were no different from those of the control group at a minimum 1-year follow-up.<sup>22</sup> In fact, logistic regression analysis of both groups demonstrated that the use of PRFM was a significant predictor of tendon defect at 12-week follow-up ( $P = 0.037$ ), suggesting that it may have a negative effect on healing. The authors postulated that the variability in the composition and quality of PRP for each patient likely led to variability in the capacity for tendon repair. In a prospective cohort study involving 42 patients, Jo et al<sup>23</sup> demonstrated that, compared with the control group, application of PRP gel

**Figure 3**



Axial magnetic resonance images of the gap area (dotted line near the top of panel A; arrow, panel B) of the patellar tendon harvest site in a patient who did not receive platelet-rich plasma (PRP) (A) and a patient who did receive PRP (B). The gap is smaller in panel B than in panel A. (Adapted with permission from de Almeida AM, Demange MK, Sobrado MF, Rodrigues MB, Pedrinelli A, Hernandez AJ: Patellar tendon healing with platelet-rich plasma: A prospective randomized controlled trial. *Am J Sports Med* 2012;40[6]:1282-1288.)

to arthroscopic rotator cuff repairs did not accelerate recovery with respect to pain, motion, strength, or overall patient satisfaction at any time point up to a minimum of 16 months postoperatively. The difference in re-tear rate between the groups at 9-month follow-up was not statistically significant.

Conversely, in a double-blind RCT of 53 patients, intraoperative application of PRP with an autologous thrombin component during arthroscopic rotator cuff repair led to significantly higher Constant and University of California, Los Angeles scores and strength in external rotation 3 months after surgery but not at 6, 12, and 24 months compared with control subjects.<sup>15</sup> In grade 1 and 2 tears, the use of PRP led to significantly higher strength in external rotation scores at 3, 6, 12, and 24 months postoperatively ( $P < 0.05$ ) and a lower rate of re-rupture ( $P = 0.08$ ). Notably, Randelli et al<sup>15</sup> used a commercial preparation of PRP

different from that used by Castricini et al<sup>14</sup> and Rodeo et al.<sup>22</sup>

In a randomized trial involving 40 patients with subacromial decompression, the use of PRP led to significantly decreased pain scores and improved shoulder range of motion postoperatively compared with that of control patients ( $P < 0.001$ ).<sup>16</sup> Despite this, a systematic review performed by Chahal et al<sup>61</sup> concluded that PRP does not have an effect on re-tear rates or clinical outcomes after arthroscopic repair. Although there is some evidence demonstrating potential benefit, further study is required before the routine use of adjunctive PRP during shoulder surgery can be recommended.

### Achilles Tendon Repair

Achilles tendon ruptures can be associated with prolonged recovery and postoperative complications such as re-rupture because of the poor vascular environment surrounding the re-

pair. In a case-control study involving 12 athletes who had acute Achilles tendon repair, patients who were injected with a preparation rich in growth factors around the tendon fibers demonstrated significantly faster recovery of range of motion ( $P = 0.025$ ) and time to running ( $P = 0.042$ ).<sup>30</sup> However, a level II study of 30 patients who underwent Achilles tendon repair with or without PRP administration demonstrated no significant difference between the two groups in heel raise index or elasticity modulus at 1-year follow-up.<sup>24</sup> In fact, the Achilles Tendon Total Rupture Score was lower in the PRP group, which suggests that intraoperative use of PRP may be detrimental. Because the formulation of PRP used in this study was 17 times that of baseline platelets without WBCs, the difference in preparations could have contributed to the conflicting results.

Although no significant difference in clinical outcomes has been found, preliminary clinical evidence suggests that PRP may be beneficial during the ligamentization and maturation processes of graft healing as well as that of the patellar tendon graft harvest sites in ACL reconstruction. For rotator cuff and Achilles tendon repairs, the results of clinical studies are equivocal, and further study is needed before definitive conclusions can be drawn and recommendations made.

### Cost-benefit Considerations

As the quality of investigational studies regarding PRP increases, so too will the demand for its clinical use. The market for PRP, valued at \$45 million in 2009, is expected to grow to \$126 million by 2016.<sup>62</sup>

Although the body of evidence for the use of PRP in orthopaedic conditions is rapidly expanding, insufficient evidence exists to perform an

adequate cost-benefit analysis. PRP therapy is not covered by many insurance plans in the United States, and until appropriate data are available, this situation may not change. In a study involving diabetic wound ulcers, the cost of PRP treatment in 2006 was estimated to be \$450 per treatment, for a monthly cost of \$3,600 for an uncomplicated ulcer.<sup>63</sup> Dougherty<sup>63</sup> concluded that PRP gel was more cost-effective than wet-to-dry saline dressings in managing nonhealing diabetic foot ulcers over a 5-year period.

In the Netherlands, PRP treatment costs approximately twice as much as corticosteroid treatment but just half that of surgical débridement.<sup>6</sup> Although the short-term costs of PRP are greater than those of standard steroid injections, if the incidence of further intervention (ie, surgery, re-injection) is decreased at long-term follow-up or if satisfaction is significantly greater with PRP, then an overall cost savings can be realized. Gosens et al<sup>6</sup> suggested that PRP may be less expensive than corticosteroids at 2-year follow-up in the management of lateral epicondylitis.

In the orthopaedic literature, future research with data from EuroQoL-5D measures would greatly enhance the ability to implement a cost-benefit analysis. More importantly, comparison groups would have to be properly chosen in such a study. Cost analysis would have to be compared with a surgical intervention. Proper economic evaluation must take into account reported success rates, timing of treatment, and the patient population.

### Summary

Although PRP has a theoretic benefit in the augmentation of tissue healing, the evidence-based literature

suggests that success varies depending on the preparation method and composition, medical condition of the patient, anatomic location, and tissue type. In response to a growing interest among both patients and surgeons in the use of PRP, recent studies have reported outcomes in a variety of conditions. Further critical review and rigorous clinical studies are required to formulate a cost-effective, efficacious algorithm for the use of PRP in patients with orthopaedic conditions.

### References

*Evidence-based Medicine:* Levels of evidence are described in the table of contents. In this article, references 2-16 are level I studies. References 17-24 are level II studies. References 25-30 are level III studies.

References printed in **bold type** are those published within the past 5 years.

1. **PRP an Unproven Option, Say Experts.** Available at: [http://www.aaos.org/news/acadnews/2011/AAOS1\\_2\\_16.asp](http://www.aaos.org/news/acadnews/2011/AAOS1_2_16.asp). Accessed September 23, 2013.
2. Patel S, Dhillon MS, Aggarwal S, Marwaha N, Jain A: Treatment with platelet-rich plasma is more effective than placebo for knee osteoarthritis: A prospective, double-blind, randomized trial. *Am J Sports Med* 2013;41(2):356-364.
3. Cerza F, Carni S, Carcangiu A, et al: Comparison between hyaluronic acid and platelet-rich plasma, intra-articular infiltration in the treatment of gonarthrosis. *Am J Sports Med* 2012; 40(12):2822-2827.
4. Filardo G, Kon E, Di Martino A, et al: Platelet-rich plasma vs hyaluronic acid to treat knee degenerative pathology: Study design and preliminary results of a randomized controlled trial. *BMC Musculoskelet Disord* 2012;13:229.
5. Thanasis C, Papadimitriou G, Charalambidis C, Paraskevopoulos I, Papanikolaou A: Platelet-rich plasma versus autologous whole blood for the treatment of chronic lateral elbow epicondylitis: A randomized controlled clinical trial. *Am J Sports Med* 2011; 39(10):2130-2134.



6. Gosens T, Peerbooms JC, van Laar W, den Oudsten BL: Ongoing positive effect of platelet-rich plasma versus corticosteroid injection in lateral epicondylitis: A double-blind randomized controlled trial with 2-year follow-up. *Am J Sports Med* 2011;39(6):1200-1208.
7. Peerbooms JC, Sluimer J, Bruijn DJ, Gosens T: Positive effect of an autologous platelet concentrate in lateral epicondylitis in a double-blind randomized controlled trial: Platelet-rich plasma versus corticosteroid injection with a 1-year follow-up. *Am J Sports Med* 2010;38(2):255-262.
8. de Vos RJ, Weir A, van Schie HT, et al: Platelet-rich plasma injection for chronic Achilles tendinopathy: A randomized controlled trial. *JAMA* 2010;303(2):144-149.
9. de Jonge S, de Vos RJ, Weir A, et al: One-year follow-up of platelet-rich plasma treatment in chronic Achilles tendinopathy: A double-blind randomized placebo-controlled trial. *Am J Sports Med* 2011;39(8):1623-1629.
10. Gosens T, Den Oudsten BL, Fievez E, van 't Spijker P, Fievez A: Pain and activity levels before and after platelet-rich plasma injection treatment of patellar tendinopathy: A prospective cohort study and the influence of previous treatments. *Int Orthop* 2012;36(9):1941-1946.
11. Nin JR, Gasque GM, Azcárate AV, Beola JD, Gonzalez MH: Has platelet-rich plasma any role in anterior cruciate ligament allograft healing? *Arthroscopy* 2009;25(11):1206-1213.
12. Cervellini M, de Girolamo L, Bait C, Denti M, Volpi P: Autologous platelet-rich plasma gel to reduce donor-site morbidity after patellar tendon graft harvesting for anterior cruciate ligament reconstruction: A randomized, controlled clinical study. *Knee Surg Sports Traumatol Arthrosc* 2012;20(1):114-120.
13. de Almeida AM, Demange MK, Sobrado MF, Rodrigues MB, Pedrinelli A, Hernandez AJ: Patellar tendon healing with platelet-rich plasma: A prospective randomized controlled trial. *Am J Sports Med* 2012;40(6):1282-1288.
14. Castricini R, Longo UG, De Benedetto M, et al: Platelet-rich plasma augmentation for arthroscopic rotator cuff repair: A randomized controlled trial. *Am J Sports Med* 2011;39(2):258-265.
15. Randelli P, Arrigoni P, Ragone V, Aliprandi A, Cabitza P: Platelet rich plasma in arthroscopic rotator cuff repair: A prospective RCT study, 2-year follow-up. *J Shoulder Elbow Surg* 2011;20(4):518-528.
16. Everts PA, Devilee RJ, Brown Mahoney C, et al: Exogenous application of platelet-leukocyte gel during open subacromial decompression contributes to improved patient outcome: A prospective randomized double-blind study. *Eur Surg Res* 2008;40(2):203-210.
17. Bibbo C, Bono CM, Lin SS: Union rates using autologous platelet concentrate alone and with bone graft in high-risk foot and ankle surgery patients. *J Surg Orthop Adv* 2005;14(1):17-22.
18. Mei-Dan O, Carmont MR, Laver L, Mann G, Maffulli N, Nyska M: Platelet-rich plasma or hyaluronate in the management of osteochondral lesions of the talus. *Am J Sports Med* 2012;40(3):534-541.
19. Mishra A, Pavelko T: Treatment of chronic elbow tendinosis with buffered platelet-rich plasma. *Am J Sports Med* 2006;34(11):1774-1778.
20. Silva A, Sampaio R: Anatomic ACL reconstruction: Does the platelet-rich plasma accelerate tendon healing? *Knee Surg Sports Traumatol Arthrosc* 2009;17(6):676-682.
21. Orrego M, Larrain C, Rosales J, et al: Effects of platelet concentrate and a bone plug on the healing of hamstring tendons in a bone tunnel. *Arthroscopy* 2008;24(12):1373-1380.
22. Rodeo SA, Delos D, Williams RJ, Adler RS, Pearle A, Warren RF: The effect of platelet-rich fibrin matrix on rotator cuff tendon healing: A prospective, randomized clinical study. *Am J Sports Med* 2012;40(6):1234-1241.
23. Jo CH, Kim JE, Yoon KS, et al: Does platelet-rich plasma accelerate recovery after rotator cuff repair? A prospective cohort study. *Am J Sports Med* 2011;39(10):2082-2090.
24. Schepull T, Kvist J, Norrman H, Trinks M, Berlin G, Aspenberg P: Autologous platelets have no effect on the healing of human achilles tendon ruptures: A randomized single-blind study. *Am J Sports Med* 2011;39(1):38-47.
25. Tsai CH, Hsu HC, Chen YJ, Lin MJ, Chen HT: Using the growth factors-enriched platelet glue in spinal fusion and its efficiency. *J Spinal Disord Tech* 2009;22(4):246-250.
26. Carreon LY, Glassman SD, Anekstein Y, Puno RM: Platelet gel (AGF) fails to increase fusion rates in instrumented posterolateral fusions. *Spine (Phila Pa 1976)* 2005;30(9):E243-E246, discussion E247.
27. Weiner BK, Walker M: Efficacy of autologous growth factors in lumbar intertransverse fusions. *Spine (Phila Pa 1976)* 2003;28(17):1968-1970, discussion 1971.
28. Filardo G, Kon E, Della Villa S, Vincentelli F, Fornasari PM, Marcacci M: Use of platelet-rich plasma for the treatment of refractory jumper's knee. *Int Orthop* 2010;34(6):909-915.
29. Radice F, Yáñez R, Gutiérrez V, Rosales J, Pinedo M, Coda S: Comparison of magnetic resonance imaging findings in anterior cruciate ligament grafts with and without autologous platelet-derived growth factors. *Arthroscopy* 2010;26(1):50-57.
30. Sánchez M, Anita E, Azofra J, Andía I, Padilla S, Mujika I: Comparison of surgically repaired Achilles tendon tears using platelet-rich fibrin matrices. *Am J Sports Med* 2007;35(2):245-251.
31. Marx RE: Platelet-rich plasma: Evidence to support its use. *J Oral Maxillofac Surg* 2004;62(4):489-496.
32. Tayapongsak P, O'Brien DA, Monteiro CB, Arceo-Diaz LY: Autologous fibrin adhesive in mandibular reconstruction with particulate cancellous bone and marrow. *J Oral Maxillofac Surg* 1994;52(2):161-165, discussion 166.
33. Hall MP, Band PA, Meislin RJ, Jazrawi LM, Cardone DA: Platelet-rich plasma: Current concepts and application in sports medicine. *J Am Acad Orthop Surg* 2009;17(10):602-608.
34. Mazzocca AD, McCarthy MB, Chowanec DM, et al: Platelet-rich plasma differs according to preparation method and human variability. *J Bone Joint Surg Am* 2012;94(4):308-316.
35. DeLong JM, Russell RP, Mazzocca AD: Platelet-rich plasma: The PAW classification system. *Arthroscopy* 2012;28(7):998-1009.
36. Wasterlain AS, Braun HJ, Harris AH, Kim HJ, Dragoo JL: The systemic effects of platelet-rich plasma injection. *Am J Sports Med* 2013;41(1):186-193.
37. Harris SE, Bonewald LF, Harris MA, et al: Effects of transforming growth factor beta on bone nodule formation and expression of bone morphogenetic protein 2, osteocalcin, osteopontin, alkaline phosphatase, and type I collagen mRNA in long-term cultures of fetal rat calvarial osteoblasts. *J Bone Miner Res* 1994;9(6):855-863.
38. Han B, Woodell-May J, Ponticello M, Yang Z, Nimmi M: The effect of thrombin activation of platelet-rich plasma on demineralized bone matrix osteoinductivity. *J Bone Joint Surg Am* 2009;91(6):1459-1470.
39. Castillo TN, Pouliot MA, Kim HJ, Dragoo JL: Comparison of growth factor and platelet concentration from commercial platelet-rich plasma separation systems. *Am J Sports Med* 2011;39(2):266-271.

40. Sundman EA, Cole BJ, Fortier LA: Growth factor and catabolic cytokine concentrations are influenced by the cellular composition of platelet-rich plasma. *Am J Sports Med* 2011;39(10):2135-2140.
41. Metcalf KB, Mandelbaum BR, McIlwraith CW: Application of platelet-rich plasma to disorders of the knee joint. *Cartilage* 2013;4(4):295-312.
42. Harvest Terumo: SmartPrep2: The Optimal Platelet Rich Plasma Composition. Available at: <http://www.harvesttech.com/pdf/SL-021-0961-PRPCorporateBrochure.pdf>. Accessed October 3, 2013.
43. Fallouh L, Nakagawa K, Sasho T, et al: Effects of autologous platelet-rich plasma on cell viability and collagen synthesis in injured human anterior cruciate ligament. *J Bone Joint Surg Am* 2010;92(18):2909-2916.
44. Leitner GC, Koszik F, Rudnicki T, et al: Apheresis products of the Amicus and the AS.TEC 204 cell separators are comparable with regard to dendritic cells derived from the mononuclear cell collection. *Vox Sang* 2007;92(1):37-41.
45. Mazzucco L, Balbo V, Cattana E, Guaschino R, Borzini P: Not every PRP-gel is born equal: Evaluation of growth factor availability for tissues through four PRP-gel preparations. Fibrinet, RegenPRP-Kit, Plateltext and one manual procedure. *Vox Sang* 2009;97(2):110-118.
46. Weibrich G, Kleis WK, Hitzler WE, Hafner G: Comparison of the platelet concentrate collection system with the plasma-rich-in-growth-factors kit to produce platelet-rich plasma: A technical report. *Int J Oral Maxillofac Implants* 2005;20(1):118-123.
47. Giusti I, Rughetti A, D'Ascenzo S, et al: Identification of an optimal concentration of platelet gel for promoting angiogenesis in human endothelial cells. *Transfusion* 2009;49(4):771-778.
48. Mishra A, Harmon K, Woodall J, Vieira A: Sports medicine applications of platelet rich plasma. *Curr Pharm Biotechnol* 2012;13(7):1185-1195.
49. Okamoto S, Ikeda T, Sawamura K, et al: Positive effect on bone fusion by the combination of platelet-rich plasma and a gelatin  $\beta$ -tricalcium phosphate sponge: A study using a posterolateral fusion model of lumbar vertebrae in rats. *Tissue Eng Part A* 2012;18(1-2):157-166.
50. Iqbal J, Pepkowitz SH, Klapper E: Platelet-rich plasma for the replenishment of bone. *Curr Osteoporos Rep* 2011;9(4):258-263.
51. Leitner GC, Gruber R, Neumüller J, et al: Platelet content and growth factor release in platelet-rich plasma: A comparison of four different systems. *Vox Sang* 2006;91(2):135-139.
52. American Academy of Orthopaedic Surgeons: *Treatment of Osteoarthritis of the Knee: Evidence-Based Guideline, 2nd Edition*. Available at: <http://www.aaos.org/research/guidelines/TreatmentofOsteoarthritisoftheKneeGuideline.pdf>. Accessed October 3, 2013.
53. Pierce GF, Mustoe TA, Lingelbach J, Masakowski VR, Gramates P, Deuel TF: Transforming growth factor beta reverses the glucocorticoid-induced wound-healing deficit in rats: Possible regulation in macrophages by platelet-derived growth factor. *Proc Natl Acad Sci U S A* 1989;86(7):2229-2233.
54. Marx RE: Platelet-rich plasma (PRP): What is PRP and what is not PRP? *Implant Dent* 2001;10(4):225-228.
55. Murray MM, Spindler KP, Ballard P, Welch TP, Zurakowski D, Nanney LB: Enhanced histologic repair in a central wound in the anterior cruciate ligament with a collagen-platelet-rich plasma scaffold. *J Orthop Res* 2007;25(8):1007-1017.
56. Sánchez M, Anitua E, Azofra J, Prado R, Muruzabal F, Andia I: Ligamentization of tendon grafts treated with an endogenous preparation rich in growth factors: Gross morphology and histology. *Arthroscopy* 2010;26(4):470-480.
57. Vavken P, Sadoghi P, Murray MM: The effect of platelet concentrates on graft maturation and graft-bone interface healing in anterior cruciate ligament reconstruction in human patients: A systematic review of controlled trials. *Arthroscopy* 2011;27(11):1573-1583.
58. Magnussen RA, Flanigan DC, Pedroza AD, Heinlein KA, Kaeding CC: Platelet rich plasma use in allograft ACL reconstructions: Two-year clinical results of a MOON cohort study. *Knee* 2013;20(4):277-280.
59. Kartus J, Magnusson L, Stener S, Brandsson S, Eriksson BI, Karlsson J: Complications following arthroscopic anterior cruciate ligament reconstruction: A 2-5-year follow-up of 604 patients with special emphasis on anterior knee pain. *Knee Surg Sports Traumatol Arthrosc* 1999;7(1):2-8.
60. Visentini PJ, Khan KM, Cook JL, Kiss ZS, Harcourt PR, Wark JD; Victorian Institute of Sport Tendon Study Group: The VISA score: An index of severity of symptoms in patients with jumper's knee (patellar tendinosis). *J Sci Med Sport* 1998;1(1):22-28.
61. Chahal J, Van Thiel GS, Mall N, et al: The role of platelet-rich plasma in arthroscopic rotator cuff repair: A systematic review with quantitative synthesis. *Arthroscopy* 2012;28(11):1718-1727.
62. GlobalData: *Platelet Rich Plasma: A Market Snapshot*. Available at: <http://www.docstoc.com/docs/47503668/Platelet-Rich-Plasma-A-Market-Snapshot>. Accessed September 17, 2013.
63. Dougherty EJ: An evidence-based model comparing the cost-effectiveness of platelet-rich plasma gel to alternative therapies for patients with nonhealing diabetic foot ulcers. *Adv Skin Wound Care* 2008;21(12):568-575.